

## MORPHOLOGICAL MALFORMATIONS IN LIMBS AND SKELETAL STRUCTURES INDUCED BY RETINOIC ACID IN MOUSE EMBRYO (NMRI)\*

A. AMINI\*\*, M. NAJAFI MEHR AND M. R. SAFAEE SHIRAZI

Faculty of Science, Biology Department, Laboratory of Developmental Biology  
Razi University, Kermanshah, I.R. of Iran  
E-mail: aminial@yahoo.com

**Abstract** – Retinoic acid (RA) plays a key role in pattern formation along the major body axis and limb formation during vertebrate development. Exposure to excessive retinoic acid (in uterus) generates congenital malformations in limbs, craniofacial, CNS, urogenital, heart, and axial skeletons. In these studies, seven groups of NMRI pregnant mice were administered a single gavage dose of 100 mg /kg body weight; All-trans-retinoic acid dissolved in DMSO at days 9, 10, and 11 of gestation (groups 2, 4, 6), DMSO at days 9, 10, and 11 (groups 1, 3, 5) and left (control group) untreated. Animals were sacrificed at day 18 of gestation via cesarean. Half of the total numbers (n=115) of fetuses were randomly selected for histological studies, using hematoxylin-eosin methods, and others were used to study the skeletal defects. It was demonstrated that embryonic exposure to RA reveals that on day 9, 37 % of forelimbs and 31% of hindlimbs have some abnormalities, and on days 10 and 11, 100% show defects on craniofacial, vertebral column, ribs and limbs.

**Keywords** – Retinoic acid, skeletal development, teratogenesis, congenital malformation

### 1. INTRODUCTION

It has long been known that retinol (vitamin A) is essential for normal growth, vision, reproduction, maintenance of numerous tissues, and overall survival of embryos [1, 2]. Retinoic acid (RA), which exists in both *cis* and *trans* isomeric forms, is the most biologically active metabolite of vitamin A and is also essential for normal development [3, 4]. RA is generated from retinol and other carotenoids through the body metabolism [5, 6]. All-trans RA is a potential regulator of cell proliferation and differentiation [3, 6]. Reports on the expression and function of RA-synthesizing and metabolizing enzymes have shed new light on how RA distribution in developing tissue is finely controlled [2, 7]. Retinoids have also become powerful tools in clinical practices for a wide variety of diseases from acne to leukemia [8, 9]. Retinoids can also halt the progression of premalignant lesions of leukoplakia to malignancy [10, 11]. RA is able to induce the transcription of a number of genes, some of which regulate important developmental events during organogenesis [12, 13]. The RA receptor gene family is composed of three receptor types, RAR $\alpha$ , RAR $\beta$  and RAR $\gamma$ , which act as ligand-activated transcriptional enhancer factors [3, 14, 15]. RA influences the expression of homeobox (Hox) and other pattern-related genes in the developing limbs, apparently through an array of RA binding proteins (CRABPs) and nuclear RA receptors [14, 16]. In humans, as well as

---

\*Received by the editor April 12, 2003 and in final revised form December 6, 2004

\*\*Corresponding author

laboratory animals, retinoids have been found to induce a characteristic pattern of malformations in craniofacial regions, the cardiovascular system, CNS, limbs, skeletal elements, the urogenital system and thymus [17, 18].

The spectacular effects of topical administration of RA on limb development have led to the proposal that RA could in fact be a morphogen [3, 9]. Administration of RA during embryogenesis has teratogenic effects. This observation led to the proposal that RA plays key roles in pattern formation along the major body axis and vertebrate limb formation [8, 19]. In mammalian embryos, RA is an active teratogen inducing stage dependent alterations in limb patterns, which in severe cases, result in almost complete elimination of the long bones [15, 20]. Administered RA during mouse embryogenesis can alter the pattern of the axial skeleton during developmental periods [3, 16]. A Single oral dose of 100 mg/kg body weight administered in the mouse on days 9, 10 and 11 after fertilization led to limb defects [1, 21].

Some malformations involving craniofacial, cardiac and nervous system structures were found in human infants exposed to isotretinoin (13-cis-RA) in utero, during the first trimester [8, 17]. Maternal therapy with 13-cis-RA, during the first trimester of pregnancy has been associated with stillbirths, spontaneous abortions and congenital malformations [6, 8]. In this study: 1) the teratogenic effects of RA during organogenesis was determined, 2) the results revealed that overdoses of RA have teratogenic effects during the developmental period.

## 2. MATERIALS AND METHODS

NMRI mice obtained from the Razi Institute were housed in an environmentally controlled room (23-25°C and 30-40% humidity) and acclimated to a 12 hour light-dark cycle (6 AM to 6 PM). The animals were maintained on Purina Lab Chow and tap water ad libitum. Females were mated with males (2:1) from 6.00 PM to 6.00 AM and the day of vaginal observation was designated as day 0 of gestation. All-trans-RA was obtained from the Sigma Chemical Company.

RA stock solutions were prepared by dissolving 100 mg of pure compound in an equal volume of dimethyl sulfoxide (DMSO). Seven groups of NMRI pregnant mice were administered a single gavage dose of 100 mg/kg body weight (b.w.) dissolved all-trans RA in DMSO, on days 9, 10 and 11 of gestation (experimental groups 2,4,6) and DMSO on days 9, 10 and 11 (experimental groups 1, 3, 5) and left (control group) untreated. Animals were sacrificed on day 18, under ether semi-anesthesia. Half of the total number (n=115) of fetuses were randomly selected and fixed in formaldehyde for histological studies. After tissue processing, histological sections (longitudinal) were made and stained with hematoxylin- eosin. The rest (n=115) were used for whole mount skeletal analysis. Soft tissues were dissolved in 1% KOH, and skeletal structures had been stained by Alizarin red S and Alcian blue 8GX (Sigma Chemical Company). So, bone and cartilage become red and blue, respectively. The data were analyzed statistically, using student t-test.

## 3. RESULTS

Table 1 demonstrates the incidence of forelimb and hindlimb defects on 9, 10 and 11 day old embryos. The evaluation of skeletal anomalies of 18 day old fetuses showed a clear-cut teratogenic action of RA under the chosen experimental conditions. The pathogenic incidences were analyzed statistically using student t-test. The wide spectrum of congenital limb defects that are induced by RA includes morphological defects on digits (phocomelia), absence of some bones in the limbs, and some defects in the axial skeleton. Figures 1 & 2 demonstrate short limbs and limbs with bent long bones.

Figure 3 shows a wide range of digital anomalies including oligodactyly, polydactyly, adactyly and syndactyly, respectively. The RA exposed embryos on day 9 have defects in 37.1 % of forelimbs and 31.4 % of hindlimbs, while those exposed on days 10 and 11 show 100% defects (Table 2).

Table 1. Incidence of limb defects (%) in 9, 10 and 11 day old embryos

Day (No. of fetuses)	No. of fetuses with forelimb defects (%)	No. of fetuses with hind limb defects
9 ( 35 )	13 ( 37.1 )	11 ( 31.4 )
10 ( 37 )	37 ( 100 )	37 ( 100 )
11 ( 33 )	33 ( 100 )	33 ( 100 )

Table 2. Experimental groups, days of administration and number of fetuses

Day of gestation	Dose	No. of Implantation	Mean No. of fetuses	No. of resorbtion	No. of fetuses
Control	0	77	8.22	3	74
9	DMSO	18	5.66	1	17
9	RA	43	5.83	8	35
10	DMSO	20	6.33	1	19
10	RA	41	7.40	4	37
11	DMSO	22	6.66	2	20
11	RA	40	5.50	7	33

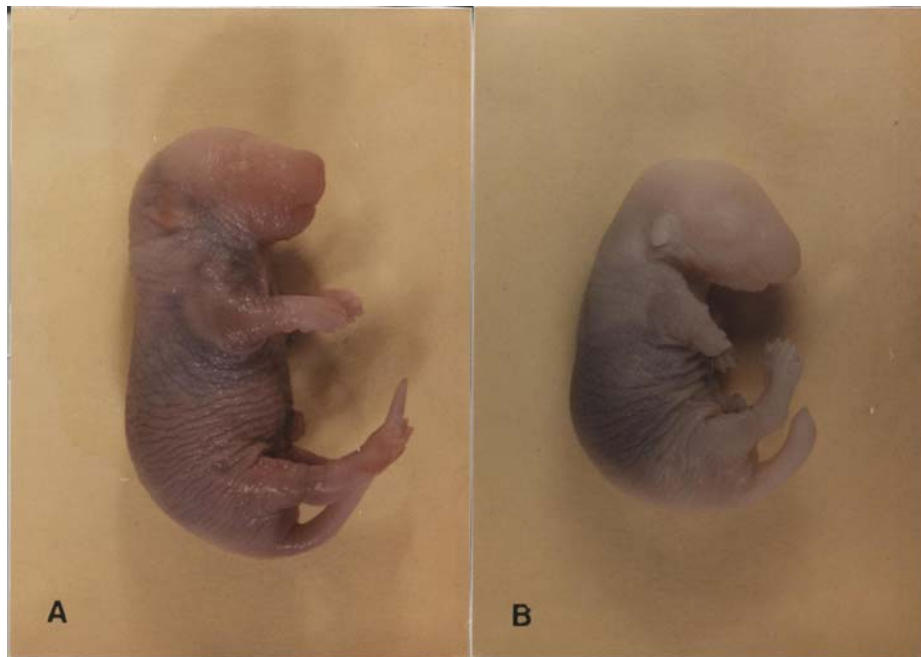


Fig. 1. Defects in limbs: A) normal embryo, B) phocomelia in 18-days old embryo exposed to RA on day 11 of pregnancy

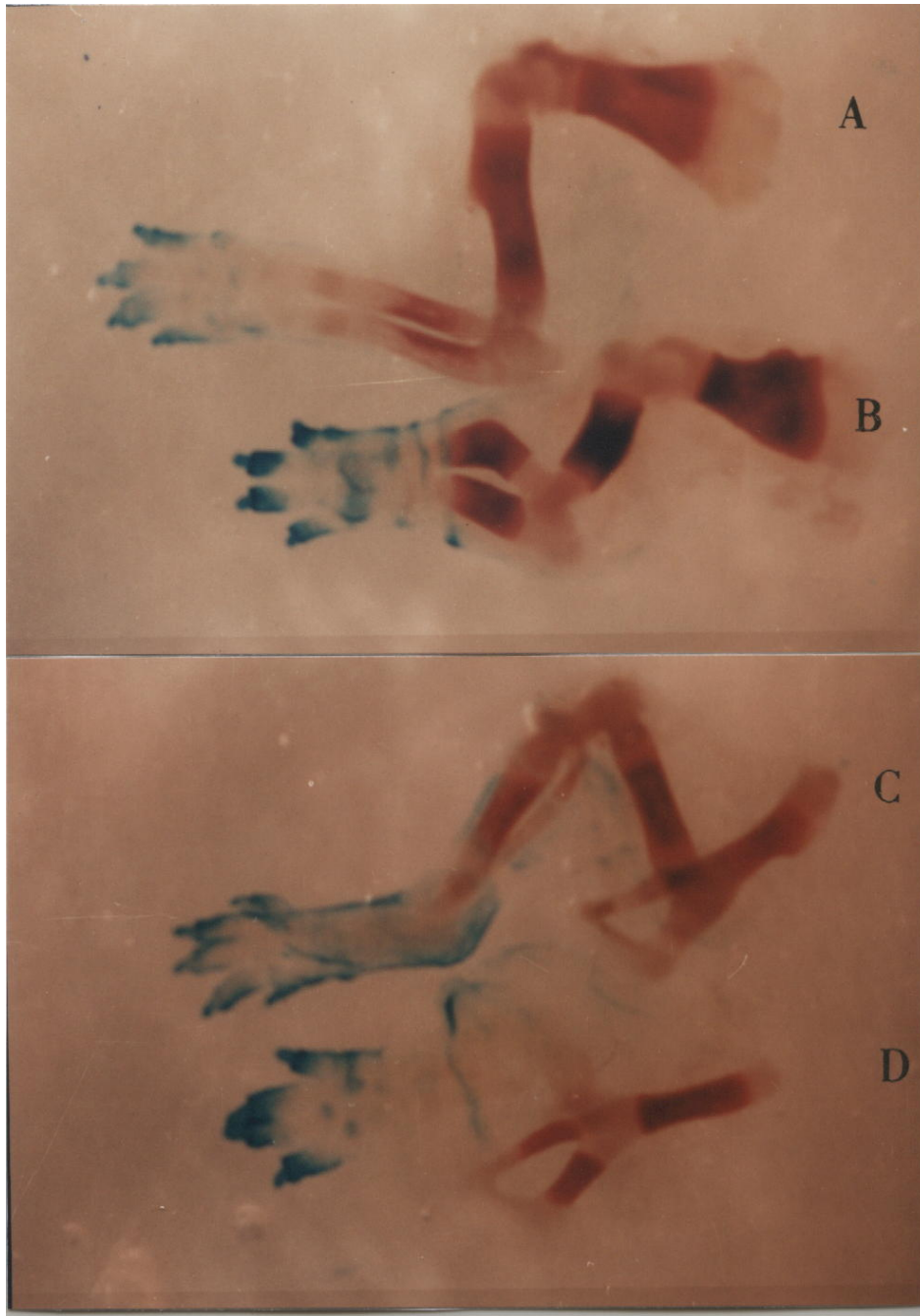


Fig. 2. Skeletal elements of limbs of 18-day old embryo: forelimb of control (A) and RA treated (B), hindlimb of control (C) and RA treated (D) groups. Notice the bent and shortening of long bones in treated (experimental) groups

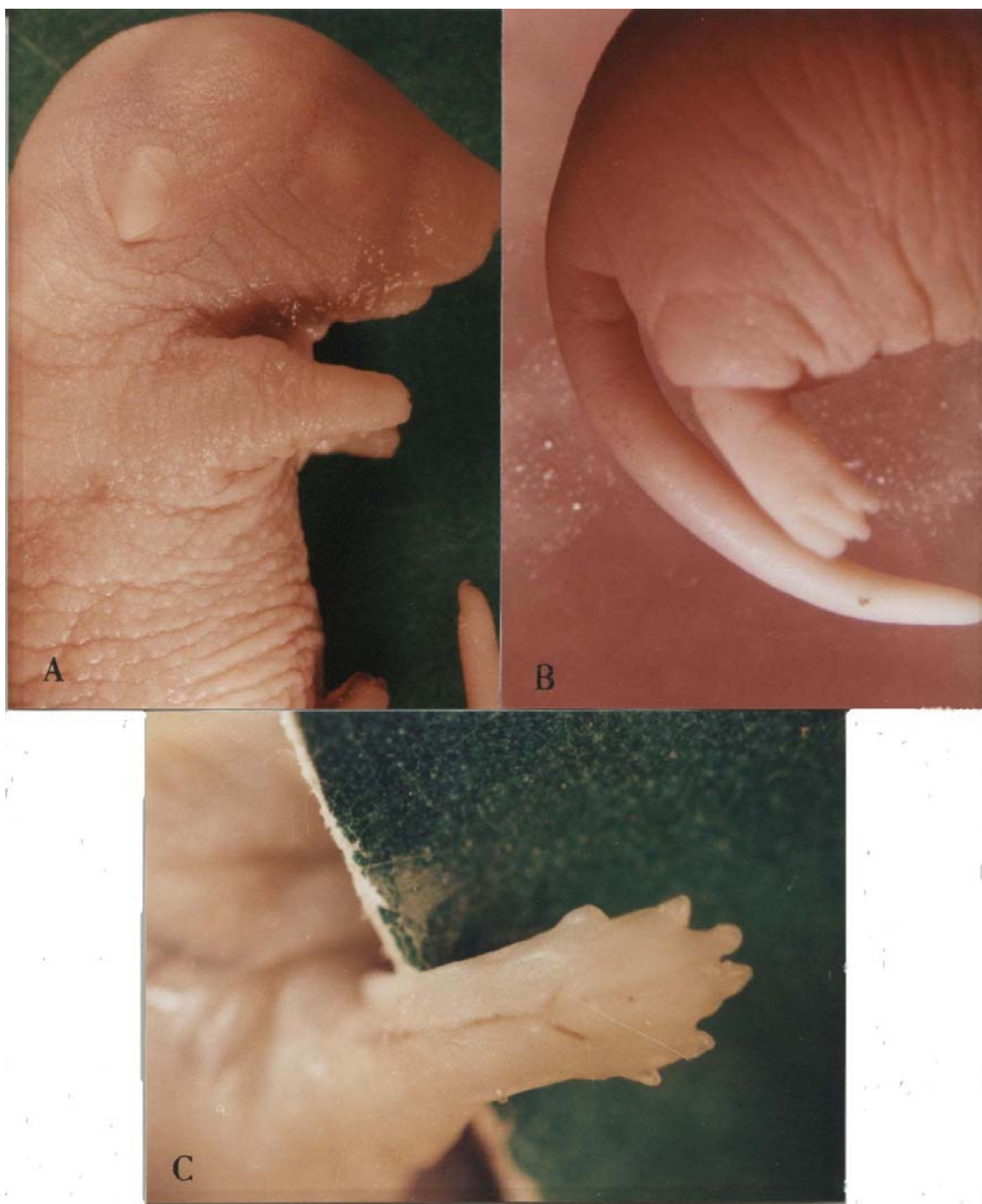

Fig. 3. Defects in RA treated embryo: A) adactyly with no digit, B) oligodactyly with 3 digits, C) polydactyly with 6 digits

In the case of the axial skeleton, embryos exposed to RA on day 11 of pregnancy showed 100% of abnormalities in craniofacial (hyperplasia of frontal bone and shortening mandible bone), vertebral column (fusion of neural arch, thickening of vertebral body and elongation of articular structure of costal tubercle) and ribs. Axial skeletal defects are monitored in Fig. 4. Apart from the mentioned defects, short lower jaw, cleft palate, shortened tail and edema were observed. No teratogenic effects were seen in the fetuses of sham groups.

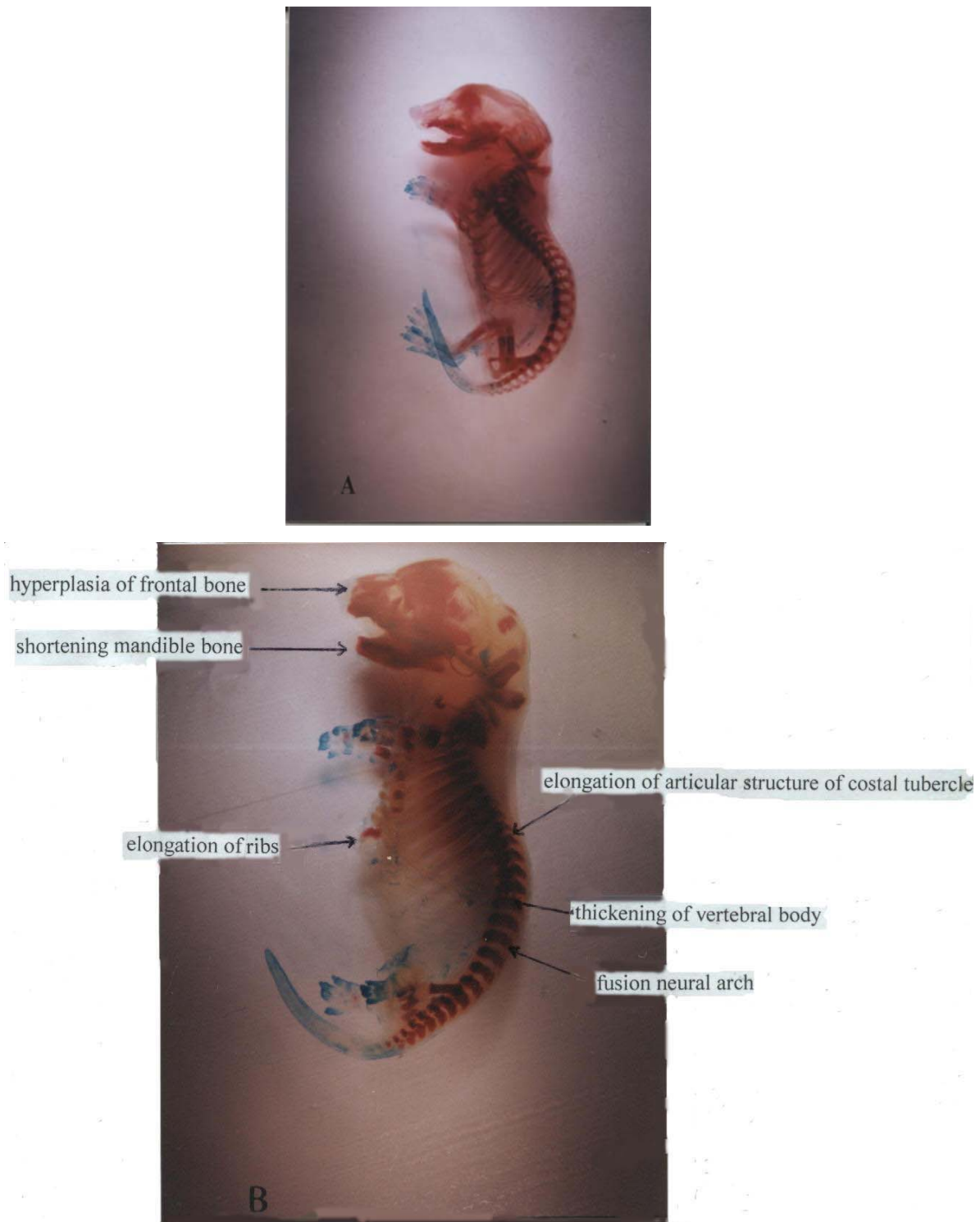


Fig. 4. Skeletal elements of 18-day old embryo: A) normal embryo (control) and B) RA treated embryo. Defects in axial skeletal are observed in craniofacial region (hyperplasia of frontal bone and shortening mandible bone), vertebral column (fusion neural arch, thickening of vertebral body and elongation of articular structure of costal tubercle) and ribs

#### 4. DISCUSSION

In this study, it was demonstrated that *in vivo* exposure of 9,10, or 11 day old mice embryos to RA, reveals defects in 37 % of forelimbs, and 31% of hindlimbs in 10 and 11 day old embryos ( $p < 0.001$ ). The mechanism by which RA induces these morphogenetic alterations has been postulated by many investigators. It has been suggested that RA is able to induce transcription of a number of genes, some of which regulate important developmental events during organogenesis [12, 13]. This action is mediated by the nuclear RA receptors, which act as ligand-activated transcriptional enhancer factors. RA affects limb skeletal pattern (*in vivo*) and has a central role in normal limb morphogenesis [1, 16]. In mammalian embryos, RA is an active teratogen and induces stage dependent alterations in limb formation, which in severe cases, result in almost complete elimination of the long bones [15, 16]. RA influences the expression of homeobox (Hox) and other pattern-related genes in the developing limbs, apparently through an array of cytoplasmic RA binding proteins (CRABPs) and nuclear RA receptors [18]. Administration of excessive RA during embryogenesis have teratogenic effects, which leads to a proposal that it plays a key role in the pattern formation of major body axis and vertebrate limb formation [8, 19]. Retinoids affect both mesenchyme and ectoderm in the limb development, while region-specific and tissue-specific expression patterns exist for the various retinoid-binding proteins and receptors, (examples present in both ectoderm and mesenchyme) [20]. Single oral doses of 100 mg/kg RA in mouse on days 9, 10 and 11 of gestation lead to defects in limbs [8, 21]. Oral administration of 100 mg/kg RA in mouse, at 10.5 or 11.5 day of gestation, has also caused defects in the craniofacial region, skeleton and both limbs [1, 21].

While DMSO is associated with inducing some malformations such as the cardiovascular system, human embryonic-fetal hematopoiesis and initiation of the limb bud development, whereas a low dose of this substance has no significant teratogenic effects after day 9 of gestation in mouse embryos [22-25].

The findings demonstrate that exposure to RA reveals defects in 37.1% of forelimb, and 31.4% of hindlimbs, on day 9, and 100% on days 10 and 11, as well as 100% of axial skeleton defects in the craniofacial region, (hyperplasia of frontal bone and shortening mandible bone), vertebral column (fusion neural arch, thickening of vertebral body and elongation of articular structure of costal tubercle) and ribs.

#### REFERENCES

1. Lohnes, D., Mark, M., Mendelsohn, C., Dolle, P. & Dierich, A. (1994). Function of the retinoic acid receptor (RARs) during development. *Development*, 120, 2723.
2. Niederreither, K., Ward, S., Dolle, P. & Chambon, P. (1996). Morphological and molecular characterization of retinoic acid induced limb duplications in mice. *Developmental biology*, 176, 185.
3. Abu-Abed, S., MacLean, G., Fraulon, V., Chambon, P., Ppetkovich, M. & Dolle, P. (2002). Differential expression of the Retinoic Acid-metabolizing Enzymes CYP26A1 and CYP26 B1 during Murine Organogenesis. *Mechanisms of Development*, 110, 173.
4. Kummet, T. & Meyskens, F. (1983). Vitamin A: A Potential Inhibitor of Human Cancer. *Seminars in Oncology*, 10, 281.
5. Jiang, H. & Kochhar, D. M. (1992). Induction of tissue transglutaminase and apoptosis by retinoic acid in the limb bud. *Teratology*, 46, 333.

6. Satre, M. A. & Kochhar, D. M. (1989). Elevations in the endogenous levels of the putative morphogen retinoic acid in embryonic mouse limb buds associated with limb dysmorphogenesis. *Developmental Biology*, 133, 529.
7. Ross, A. S., McCaffery, P., Darager, U. & De Luca, L. (2000). Retinoids in Embryonal Development. *Physiological Reviews*, 80, 1021.
8. Kraft, J. C., Kochhar, D. M., Scott, W. J. & Nau, H. (1987). Low teratogenicity of 13-cis retinoic acid (Isotretinoin) in the mouse corresponds during organogenesis: Comparison to the All-trans isomer. *Toxicology and applied pharmacology*, 87, 474.
9. Ryu, S., Stein, J. P., Chung, T. C. & Lee, Y. J. (2000). Enhanced Apoptosis and Radiosensitization by Combined 13-cis RA and Interferon-A2, A Role of RAR-  $\beta$  Gene. *Int .J. Radiation Oncology Biol. Phys.*, 51, 785.
10. Carolyn, D. B., Helen, B. E., Christina, H. & Clayton, E. (2001). The Role of vitamin A in mitochondrial gene expression. *Diabetes Research and Clinical Practice*, 54, 11.
11. Matikanen, S., Ronni, T., Hurme, R. & Julkunen, I. (1996). Retinoic Acid Activates Interferon Regulatory Factor-1 Gene Expression in Myeloid Cells. *Blood*, 88, 114.
12. Luong, L., Ramshaw, H., Tahayato, A. & Stuart, A. (2001). Regulation of Retinoic Acid Metabolism. *Adva, Enzyme Regul.*, 41, 159.
13. Sulic, K. K. & Dehart, D. B. (1988). Retinoic acid induced limb malformations resulting from apical ectodermal ridge cell death. *Teratology*, 37, 527.
14. Becker, P. S., Zhifang, L., Tamara, P. & Joseph, A. (1996). Laminin Promotes Differentiation of NB4 Promyelocytic Leukemia Cells with All-trans Retinoic Acid. *Blood*, 88, 261.
15. Dolle, P., Ruberter, E., Kastner, P. & Petkovich, M. (1989). Differential expression of genes encoding  $\alpha$ ,  $\beta$ , and  $\gamma$  retinoic acid receptors and CRABP in the developing limbs of the mouse. *Nature*, 342, 702.
16. Iulianella, A. & Lohnes, D. (1997). Contribution of Retinoic Acid receptor Gamma to retinoic induced craniofacial and axial defects. *Developmental dynamics*, 209, 92.
17. Lofberg, B., Chahud, I., Bochert, G. & Nau, H. (1990). Teratogenicity of the 13-cis and all-trans isomers of the aromatic retinoid etretin: Correlation to transplacental pharmacokinetics in mice during organogenesis after a single oral dose. *Teratology*, 41, 707.
18. Mendelsohn, C., Mark, M., Dolle, P., Dierich, A. & Gaub, M. (1994). Retinoic acid receptor  $\beta$ 2 (RAR $\beta$ 2) null mutant mice appears normal. *Developmental biology*, 166, 246.
19. Scott, W. J., Collins, M. D., Ernst, A. N., Supp, D. M. & Potter, S. S. (1989). Enhanced expression of limb malformations and axial skeleton alternations in legless mutants by transplacental exposure to retinoic acid. *Developmental Biology*, 164, 277.
20. Paulsen, D. F. (1994). Retinoic acid in limb bud outgrowth: review and hypothesis. *Anatomy and Embryology*, 190, 399.
21. Cusic, A. M. & Dagg, C. P. (1985). Spontaneous and retinoic acid-induced postaxial polydactyly in mice. *Teratology*, 31, 49.
22. Hart, R. C., McCue, W. L., Ragland, K. J. & Winn, E. R. (1990). Avian Model for 13-cis Retinoic acid Embryopathy: Demonstration of Neural Crest Related Defects. *Teratology*, 41, 463.
23. Santo, N. C., Figureira, C. J., Martins, J. & Saldanha, C. (2003). Multidisciplinary utilization of dimethyl sulfoxide pharmacological, cellular, and molecular aspects. *Biochem. Pharmacol.*, 65, 1035.
24. Tabin, C. (1995). The initiation of the limb bud: Growth factors, Hox Genes and Retinoids. *Cells*, 80, 671.
25. Tocci, A., Parolin, I. & Gabbianelli, M. (1996). Dual action of retinoic acid on human embryonic-fetal hematopoiesis: Blockade of primitive progenitor and shift from multipotent-erythroid-monocytic to granulocytic differentiation program. *Blood*, 88, 2878.